

Immediately Loaded Champions® Implants – Implantation and the Prep Caps

For more than two decades, countless dental practices have demonstrated that more modern osseous-biophysiological skills and knowledge must be reconciled with patients' needs. Dr. Armin Nedjat (Flonheim/Germany) demonstrates how a difficult single edentulous space can be treated quickly, easily, and cost-effectively (for both the patient and the practice).

Every dentist is familiar with this scenario: A young patient comes to a consultation looking for a safe, esthetically pleasing solution for a single edentulous gap, without harming the healthy adjacent teeth - like fitting a bridge. At the same time, the treatment has to be affordable for the patient and done as fast and as painlessly as possible.

The interproximal distance of the gap should diagnostically be at least 5 mm, and horizontally at least 6-8 mm from the sinus is required radiologically. For 15 years now, I have fit almost all implants – and achieved primary stability - with immediate loading, using the MIMI® method. I insert a slightly conically-shaped implant transgingivally and "laterally compensating" into the bone through a small bone cavity. By always beginning with a conical, 3.5 mm diameter implant, you can "re-implant" with a 4.5 mm or even 5.5 mm diameter in ascending diameters. This course of action corresponds more to a modified osteotome technique than implantation in the classical sense, since the osteotome instrument is already the actual implant. The great skepticism of so many colleagues and oral surgeons towards one-piece implants many years ago proved to be unjustified, as necroses have never been observed clinically or radiologically in the well over 5,500 MIMI® prosthodontically fitted crown implants performed in our practice alone, even decades after the procedure! Necroses only occur with osseous drill holes that are done too quickly. As a result an in-growth of bone into the implant surface (of up to six months in the upper jaw) no longer occurs, because thanks to a defined compression, a one-piece implant is already fully osseointegrated from the beginning. In my opinion, "the art" with MIMI® is not implanting itself, but the avoidance of micro-movements from the moment of successful implantation until implementation of the final work. The only exception to immediate loading I found in my practice are single-rooted individual upper front teeth, with which - even with a correct bite - very often extraaxial forces of up to 40° affect the upper implant crowns from the palate. In those cases I block the implant with the approximal surfaces of the neighboring teeth for at least 10 weeks in order to be able to transfer the primary stability uninterrupted to the secondary stability.

The case described here shows in the initial images (Fig. 1-3) gap 25 to 2 an aplasia. The orthodontia of the then 20-year-old patient was completed. Increased preoperative attention was required, especially for the short clinical crown, which had to be implemented later.

The primary benefits of the transgingival/minimally-invasive method of implantation (MIMI®) of Champions® lies naturally in the "flapless", non-traumatic operation (your patients will thank you!), the easy procedure (with bone cavity monitoring using "BCC"/Bone Cavity Check probes), the enormously effective one-time session and the possibility of immediate fitting.

Following local infiltration vestibularly and palatally - even before the drilling process - I insert the tip of the yellow Champions® drill (without rotating) transgingivally at the planned implantation site until I hit bone. This way I obtain the exact mucosa thickness at the area of the operation, the mm-value of which I add to my planned bone depth. Then you drill at approx. 250 rpm with the green angular piece tending slightly palatally (Fig. 4). The already conical, yellow drill features every 2 mm start at 10 mm black laser markings so that at 16 mm I am able to insert a 10 mm Champion® transgingivally (with a 4 mm mucosa thickness), since as is generally well known it is very conducive to countersink all implant threading 1-2 mm subcrestally.

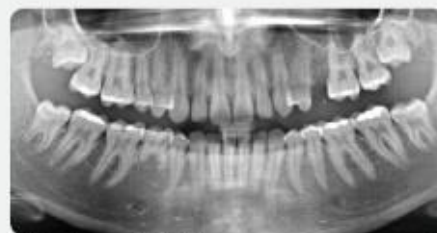

Fig. 1: Starting OPG imaging

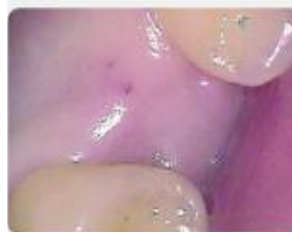

Fig. 2: Preoperative clinical situation



Fig. 3: Preoperative clinical situation

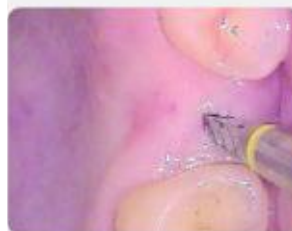

Fig. 4: MIMI® bone cavity preparation performed slightly toward the palate

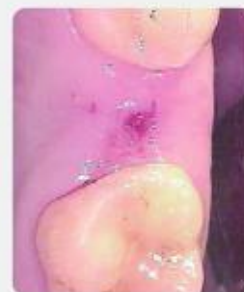

Fig. 5: MIMI® bone cavity preparation performed slightly palatally...

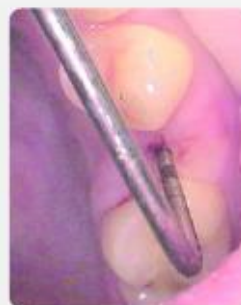

Fig. 6: ...which is checked by bone cavity monitoring ("BCC": Bone Cavity Check). All five dimensions must be palpable and surrounded with bone.



Fig. 7: With the integrated insertion aid, the Champions® - square-shaped implant is first inserted by hand up to approx. 25 Ncm "condensing laterally".

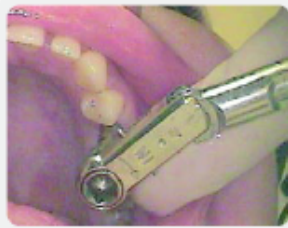

Fig. 8: The final implantation is done with at least 40 Ncm using the metal insertion aid and a torque key.

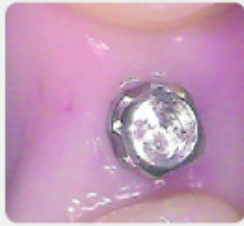

Fig. 9: Closed implantation carried out with MIMI®

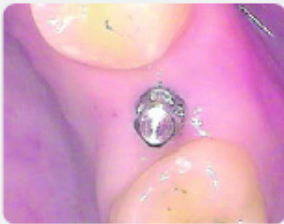

Fig. 10: Closed implantation carried out with MIMI®



Fig. 11: Closed implantation carried out with MIMI®

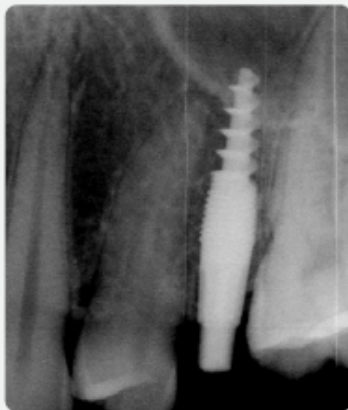


Fig. 12: X-ray checkup

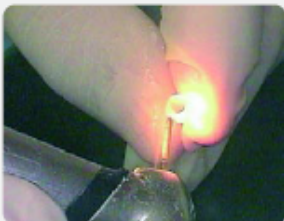


Fig. 13: The zirconium Prep-Cap, Type 1, can still be contoured extra-orally ...

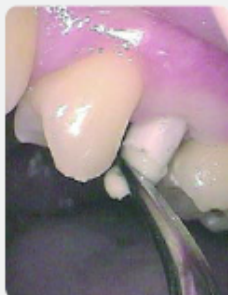

Fig. 14: ...before it is cemented with a solid glass ionomer

The minimal bone cavity must be well palpable in all five dimensions. (Fig. 6)

Perforations of the bone wall, while extremely rare, are also diagnosable and treatable with certainty.

The Champions® square-shaped implant selected is taken out of the sterile blister packaging together with the insertion aid – this avoids troublesome re-plugging of the sterile implant - and you begin to manually and slowly condense the implant in the insertion direction of the already drilled hole. At about 25 Ncm, the first insertion aid is extracted, the metal insertion aid is placed on the head of the square-shaped implant, the rotating torque wrench is placed on top of that, which is set to 40 Ncm, and the implantation process is continued. A bending of the hinged bracket at 40 Ncm only means that this 3.5 mm diameter implant can be fitted immediately and also loaded, but it does not mean that you stop condensing until you have reached the final position. A Champion® cannot be inserted more deeply than one has drilled.

The entire process from first drilling to finished implantation for skilled practitioners takes just a few minutes and is absolutely painless for patients.

I perform the x-ray checkup (Fig. 12) for among other reasons to check whether in fact the micro-thread was also inserted subcrestally at least 1 mm. It is interesting that this "subcrestal implanting" was described in a publication by two-piece implant manufacturers as "platform switching" as if it were a competitive strategy. However, it merely indicates that the head-neck-area is narrower than the implant body that is countersunk deep in the bone and that it results in bone apposition/bone formation over "the shoulder" when positioned subcrestally.

Working with a Prep-Cap

Prep-Caps made from zirconium or titanium are meso-superconstructions, which can be cemented and fit. They compensate for divergences, expand clinical crowns (as in this case) and improve peri-implant soft tissue management. In terms of the molding and laboratory manufacture, "real tooth abutments" are made from implants using PCs. Affordable material costs as well as reduced dentistry costs make it easier for many patients to decide in favor of implant-supported dental replacement.

After fitting one of five form types open at the top, the PC can also be ground extraorally with water cooling (Fig. 13) in order to obtain the optimal finish. In our practice, the PC is cemented in with conventional glass ionomer cement with a pincer (Fig. 14). The excess cement flows out orally. After hardening, if there are abutment divergences, first the "excess" titanium implant, but then also the PC itself can be prepared. The shaping is done analogous to a natural tooth (Fig. 18). An amazing secondary effect with regard to zirconium PCs was for me as a dentist the fact that a "white tooth" leaves a disproportionately more positive impression on patients than a gray titanium abutment.

After finishing the ZrO₂ solid ceramic crown, it is finally cemented in, just three days post-operatively, likewise with Fuji IX and set with shim stock foil. Even such a difficult occlusion situation - as in this case - with a short clinical crown can be esthetically optimally solved with a Champion® and PC.

Quality and a high degree of safety in the products available to us no longer contradict our guiding principles in the practice: The relationship of dentist – material – laboratory – implementation needs to be right where our interest as dentists is concerned. Because after all, we bear responsibility for the overall package. But the most important thing: Implantology, especially with the easy-to-learn MIMI® method, has become affordable for almost everyone and will make your patients true "fans" of your practice. Furthermore, Champions® can be easily integrated into our everyday practice and used spontaneously, which is invaluable when it comes to the subject of "immediate implantation" (i.e., extraction and implantation in one session).

Conclusion

The immediate loading - particularly of one-piece implants - is, with a few exceptions, to be viewed as a method that has proven effective for years - regardless of whether used in the upper or the lower jaw. The more complicated systems and work processes are, the more chance of errors, ultimately resulting in expensive failures and disappointments. I firmly believe there are no longer any medical or aesthetic arguments in favor of multi-piece systems. "Simple" Implantology, just like "minor surgery", also belongs in the hands of general dentists and prosthodontists, who along with MIMI® and Champions®, offer their patients safe, affordable, implant-supported dental replacement and who can do it without having to invest in expensive new equipment. The benefits of one-piece, compressively-inserted Champions® can be seen in the lack of micro-fissures (that can occur with multi-piece systems), the unsurpassed primary stability (thanks to its micro-threading), the "independent neck" (regardless of mucosa thickness), the complication-free MIMI® method and aftercare, the surgical and prosthodontic simplicity, and the immediate loading. The transgingivally and non-traumatically executed implantations are uncomplicated, safe to do, highly advantageous, both for the patient and the dentist, in terms of time, cost and proven effectiveness. Prep-Caps compensate abutment divergences, expand clinical crowns, improve peri-implant soft tissue, and make "real teeth" out of implants.

Dr. Armin Nedjat

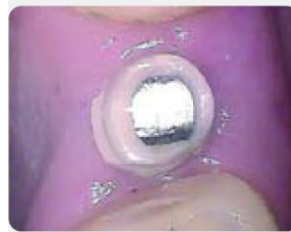

Fig. 15: Inserted zirconium Prep-Cap

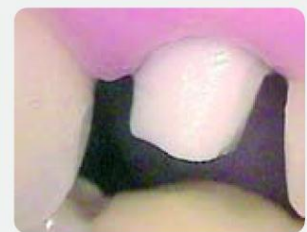

Fig. 16: Inserted zirconium Prep-Cap

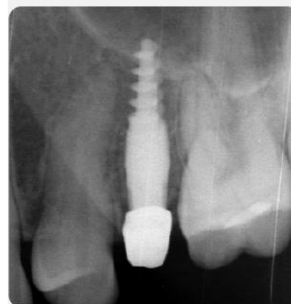

Fig. 17: X-ray check-up

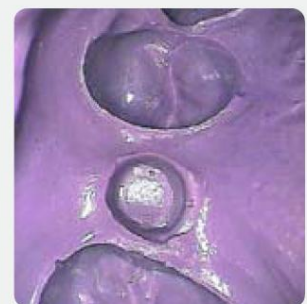

Fig. 18: Conventional impression

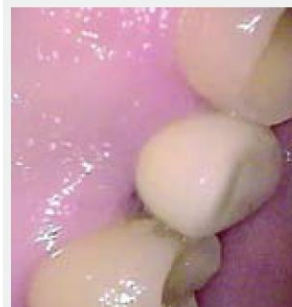

Fig. 19: Cemented in zirconium crown just four days after implantation

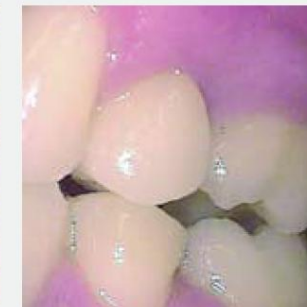

Fig. 20: Cemented in zirconium crown just four days after implantation

In addition to our homepage, please also visit the homepage of the independent "Champions Forum" at www.champions-forum.de, the website for Champions users!

Champions-Implants GmbH

Bornheimer Landstraße 8

D-55237 Flonheim

Germany

Tel.: +49 (0) 67 34 / 91 40 80

Fax: +49 (0) 67 34 / 10 53

E-Mail: info@champions-implants.com

www.champions-implants.com